

Anti-Podocalyxin Monoclonal Antibody 47-mG_{2a} Detects Lung Cancers by Immunohistochemistry

Shinji Yamada,* Shunsuke Itai,* Mika K. Kaneko, and Yukinari Kato

Lung cancer is one of the leading causes of cancer-related deaths in the world. Regardless of the advances in lung cancer treatments, the prognosis is still poor. Podocalyxin (PODXL) is a highly glycosylated type I transmembrane protein that is expressed in normal tissues, including the heart, pancreas, and breast. It is also found and used as a diagnostic marker in many cancers, such as renal, brain, breast, oral, and lung cancers. We previously developed specific and sensitive anti-PODXL monoclonal antibodies, PcMab-47 (mouse IgG₁, kappa) and its mouse IgG_{2a}-type (47-mG_{2a}), both of which were suitable for immunohistochemical analyses of oral cancers. In this study, we investigated the utility of PcMab-47 and 47-mG_{2a} for the immunohistochemical analyses of lung cancers. PcMab-47 stained 51/70 (72.9%) cases of lung cancer, whereas 47-mG_{2a} stained 59/70 (84.3%) cases, indicating that the latter antibody is more sensitive and is useful for detecting PODXL in lung cancers.

Keywords: podocalyxin, PODXL, monoclonal antibody, lung cancer

Introduction

LUNG CANCER IS ONE OF the leading causes of cancer-related deaths in the world.⁽¹⁾ The number of new cases and deaths respectively reaches about 1.8 and 1.6 million per year. There are two main subtypes: small-cell lung cancer (SCLC; 15%) and non-SCLC (NSCLC). NSCLC includes adenocarcinoma (AC), squamous cell carcinoma (SCC), and large cell carcinoma.⁽²⁾ Regardless of the advances in lung cancer treatment, the prognosis is still poor with 5-year survival rates at approximately 15%.⁽³⁾ In the early stages, lung cancer is treated via surgical removal, which can be complemented by radiotherapy and/or chemotherapy. In the advanced stages, many types of anticancer agents, including cisplatin and docetaxel, are used for chemotherapy. In recent years, some techniques for the detection and identification of cell types and genetic mutations have been established that enable accurate investigations. Some molecular targeted drugs have displayed efficacy for lung cancer under specific conditions and have been approved for treatment. These drugs include bevacizumab,⁽⁴⁾ a mouse-human IgG₁ chimeric antibody against vascular endothelial growth factor; nivolumab,⁽⁵⁾ a fully human IgG₄ monoclonal antibody (mAb) against programmed cell death 1 (PD-1); pembrolizumab,^(6,7) a mouse-human IgG₄ chimeric antibody against PD-1; and atezolizumab,⁽⁸⁾ a mouse-human IgG₁ chimeric antibody against programmed cell death ligand-1.

Podocalyxin (PODXL) is a highly *N*-glycan- and *O*-glycan-glycosylated type I transmembrane protein with a molecular weight of 150,000–200,000.^(9–12) It was originally discovered in renal podocytes and is expressed in many kinds of tissues, including the heart, pancreas, and breast. PODXL is also found in cancer tissues.⁽¹³⁾ It has been reported to be a diagnostic marker and a prognostic indicator in some cancers, such as renal,⁽¹⁴⁾ brain,⁽¹²⁾ breast,⁽¹⁵⁾ oral,⁽¹⁶⁾ and lung cancers.^(17,18) This protein is involved in tumor growth, invasion, and metastasis,⁽¹⁹⁾ and its overexpression can cause undesirable outcomes. Furthermore, Kusumoto et al. reported that PODXL overexpression induces epithelial–mesenchymal transition in lung AC and contributes to tumor progression.⁽²⁰⁾ Therefore, more precise tools for detecting PODXL in lung cancer are necessary for optimal analysis and treatment.

Previously, we established specific and sensitive anti-PODXL mAbs, PcMab-47 (mouse IgG₁, kappa), and mouse IgG_{2a}-type (47-mG_{2a}).⁽²¹⁾ Herein, we investigated the utility of these two antibodies for immunohistochemical analysis of lung cancers.

Materials and Methods

Tissues

Cancer tissue microarrays of lung cancers were purchased from US Biomax (Rockville, MD) and Cybrdi (Frederick, MD).

Department of Antibody Drug Development, Tohoku University Graduate School of Medicine, Sendai, Japan.

*These authors contributed equally to this work.

Antibodies

PcMab-47 was developed as described previously.⁽²¹⁾ Appropriate V_H and V_L cDNAs of mouse PcMab-47 and C_H and C_L of mouse IgG_{2a} were subcloned into pCAG-Ble and pCAG-Neo vectors (FUJIFILM Wako Pure Chemical Industries Ltd., Osaka, Japan), respectively, to generate 47-mG_{2a}. Antibody expression vectors were transfected into ExpiCHO-S cells using the ExpiCHO Expression System (Thermo Fisher Scientific, Inc., Waltham, MA). 47-mG_{2a} was purified using Protein G Sepharose (GE Healthcare Bio-Sciences, Pittsburgh, PA).

Immunohistochemical analyses

Histologic sections (4- μ m-thick) were deparaffinized in xylene and then rehydrated and autoclaved in citrate buffer (pH 6.0; Agilent Technologies, Inc., Santa Clara, CA) for 20 minutes. Sections were then incubated with 0.5 or 5 μ g/mL primary mAbs for 1 hour at room temperature and then treated using an Envision+ kit (Agilent Technologies, Inc.) for 30 minutes. Color development was performed using 3,3'-diaminobenzidine tetrahydrochloride (Agilent Technologies, Inc.) for 2 minutes. Sections were then counterstained with hematoxylin (FUJIFILM Wako Pure Chemical Industries Ltd.). Staining intensity was evaluated as -, 1+, 2+, or 3+.

Results and Discussion

To produce PcMab-47 (mouse IgG₁, kappa), we previously immunized mice with recombinant PODXL purified from the culture supernatant of the extracellular domain of PODXL-expressing LN229 cells.⁽²¹⁾ We further engineered PcMab-47 into a mouse IgG_{2a}-type mAb (47-mG_{2a}). This antibody exhibited a higher binding affinity than PcMab-47 for PODXL-expressing oral SCC (OSCC) cells. Immunohistochemical analysis of oral cancer tissues using these two antibodies revealed that 47-mG_{2a} stained OSCC cells in a cytoplasmic pattern at a much lower concentration. PcMab-47 and 47-mG_{2a} detected PODXL in 163/201 (81.1%) and 197/201 (98.0%) OSCC samples, respectively.

In this study, we performed immunohistochemical analyses using PcMab-47 and 47-mG_{2a} against several types of lung cancers. Typical staining results of PcMab-47 and 47-mG_{2a} against SCC, adenosquamous cell carcinoma (ASCC), small-cell carcinoma (SC), AC, bronchioloalveolar carcinoma (BC), and papillary carcinoma (PC) are shown in Figure 1 and Supplementary Figures S1–S5. Both PcMab-47 and 47-mG_{2a} stained cancer cells of all types of lung cancer in a cytoplasmic staining pattern. Furthermore, both PcMab-47 and 47-mG_{2a} stained endothelial cells in lung cancers (Fig. 2).

As shown in Table 1 and Supplementary Table S1, PcMab-47 stained 51/70 cases (72.9%) of lung cancers.

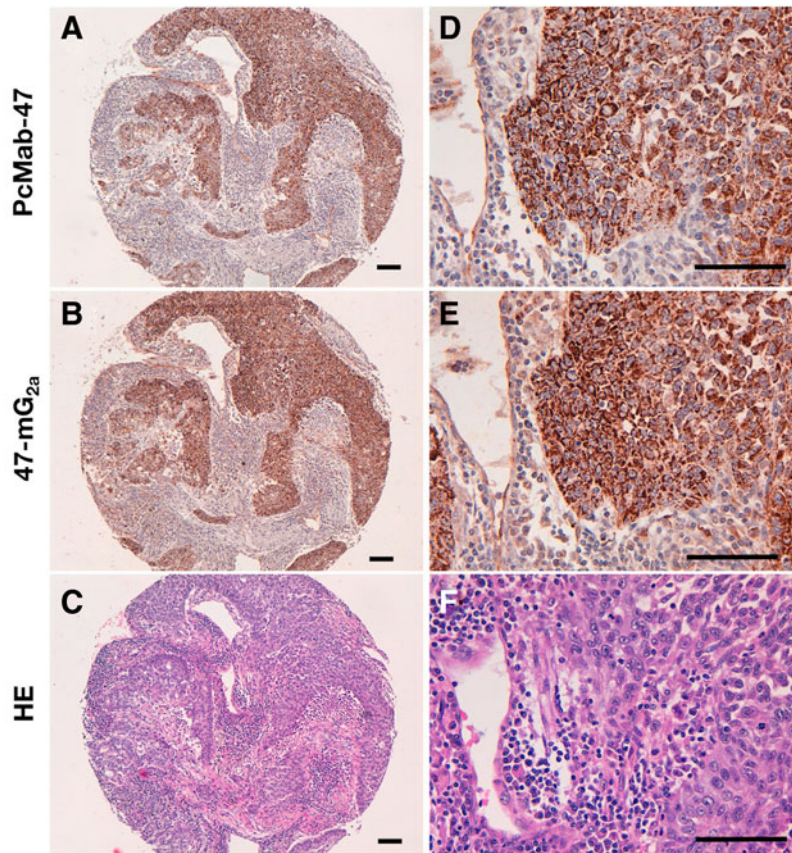


FIG. 1. Immunohistochemical analysis by anti-PODXL antibodies against lung SCCs. Sections (Case-7) were incubated with 5 μ g/mL of PcMab-47 (**A**, **D**) and 0.5 μ g/mL of 47-mG_{2a} (**B**, **E**) for 1 hour at room temperature, followed by treatment with the Envision+ kit for 30 minutes. Color development was performed using 3,3'-diaminobenzidine tetrahydrochloride for 2 minutes. Sections were then counterstained with hematoxylin. (**C**, **F**) Hematoxylin & eosin staining; scale bar = 100 μ m.

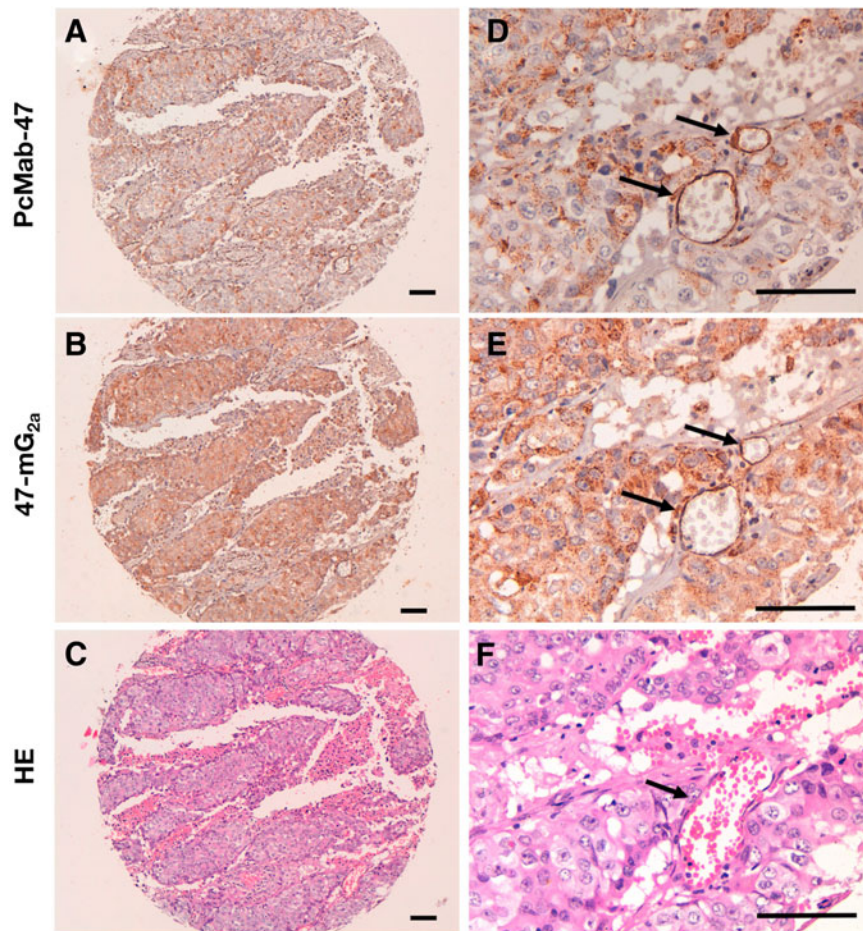


FIG. 2. Anti-PODXL antibodies detect endothelial cells in lung SCCs. Sections (Case-25) were incubated with 5 μg/mL of PcMab-47 (A, D) and 0.5 μg/mL of 47-mG_{2a} (B, E) for 1 hour at room temperature, followed by treatment with the Envision+ kit for 30 minutes. Color development was performed using 3,3-diaminobenzidine tetrahydrochloride for 2 minutes. Sections were then counterstained with hematoxylin. (C, F) Hematoxylin & eosin staining; scale bar = 100 μm; Arrows, endothelial cells.

Among them, 35/41 cases (85.4%) of SCC, 6/10 cases (60%) of ASCC, 3/7 cases (42.9%) of SC, 4/5 cases (80%) of AC, 3/5 cases (60%) of BC, and 0/2 cases (0%) of PC were stained. In contrast, 47-mG_{2a} stained 59/70 cases (84.3%) of lung cancers. Among them, 38/41 cases (92.7%) of SCC, 8/10 cases (80%) of ASCC, 4/7 cases (51.7%) of

SC, 4/5 cases (80%) of AC, 4/5 cases (80%) of BC, and 1/2 cases (50%) of PC were stained.

In conclusion, our immunohistochemical results demonstrate that 47-mG_{2a} is significantly more sensitive than the original PcMab-47 for the detection of PODXL in LSCCs and could be applied to other SCCs in the future.

TABLE 1. SUMMARY OF IMMUNOSTAINING USING PCMAb-47 AND 47-mG_{2a}

| Tumor type | No. of cases | PcMab-47 immunostaining | | | | No. of positive cases | 47-mG _{2a} immunostaining | | | | No. of positive cases |
|------------|--------------|-------------------------|----|----|----|-----------------------|------------------------------------|----|----|----|-----------------------|
| | | - | 1+ | 2+ | 3+ | | - | 1+ | 2+ | 3+ | |
| SCC | 41 | 6 | 16 | 11 | 8 | 35/41 (85.4%) | 3 | 12 | 11 | 15 | 38/41 (92.7%) |
| ASCC | 10 | 4 | 6 | 0 | 0 | 6/10 (60%) | 2 | 4 | 4 | 0 | 8/10 (80%) |
| SC | 7 | 4 | 3 | 0 | 0 | 3/7 (42.9%) | 3 | 2 | 2 | 0 | 4/7 (57.1%) |
| AC | 5 | 1 | 1 | 3 | 0 | 4/5 (80%) | 1 | 0 | 2 | 2 | 4/5 (80%) |
| BC | 5 | 2 | 2 | 1 | 0 | 3/5 (60%) | 1 | 2 | 1 | 1 | 4/5 (80%) |
| PC | 2 | 2 | 0 | 0 | 0 | 0/2 (0%) | 1 | 1 | 0 | 0 | 1/2 (50%) |
| Total | 70 | 19 | 28 | 15 | 8 | 51/70 (72.9%) | 11 | 21 | 20 | 18 | 59/70 (84.3%) |

SCC, squamous cell carcinoma; ASCC, adenosquamous cell carcinoma; SC, small-cell carcinoma; AC, adenocarcinoma; BC, bronchioloalveolar carcinoma; PC, papillary carcinoma.

The intensity of staining was evaluated as -, 1+, 2+, 3+.

Acknowledgments

We thank Takuro Nakamura, Miyuki Yanaka, Noriko Saidoh, Saori Handa, and Yoshimi Nakamura for their excellent technical assistance. This research was supported by AMED under Grant Numbers: JP17am0301010 (Y.K.), JP17am0101078 (Y.K.), and JP17ae0101028 (Y.K.).

Author Disclosure Statement

The authors have no conflicts of interest.

References

1. Ferlay J, Soerjomataram I, Dikshit R, Eser S, Mathers C, Rebelo M, Parkin DM, Forman D, and Bray F: Cancer incidence and mortality worldwide: Sources, methods and major patterns in GLOBOCAN 2012. *Int J Cancer* 2015;136:E359–E386.
2. Hassanein M, Callison JC, Callaway-Lane C, Aldrich MC, Grogan EL, and Massion PP: The state of molecular biomarkers for the early detection of lung cancer. *Cancer Prev Res (Phila)* 2012;5:992–1006.
3. Siegel R, Ward E, Brawley O, and Jemal A: Cancer statistics, 2011: The impact of eliminating socioeconomic and racial disparities on premature cancer deaths. *CA Cancer J Clin* 2011;61:212–236.
4. Johnson DH, Fehrenbacher L, Novotny WF, Herbst RS, Nemunaitis JJ, Jablons DM, Langer CJ, DeVore RF, 3rd, Gaudreault J, Damico LA, Holmgren E, and Kabbinnar F: Randomized phase II trial comparing bevacizumab plus carboplatin and paclitaxel with carboplatin and paclitaxel alone in previously untreated locally advanced or metastatic non-small-cell lung cancer. *J Clin Oncol* 2004;22:2184–2191.
5. Brahmer J, Reckamp KL, Baas P, Crino L, Eberhardt WE, Poddubskaya E, Antonia S, Pluzanski A, Vokes EE, Holgado E, Waterhouse D, Ready N, Gainor J, Aren Frontera O, Havel L, Steins M, Garassino MC, Aerts JG, Domine M, Paz-Ares L, Reck M, Baudelet C, Harbison CT, Lestini B, and Spigel DR: Nivolumab versus docetaxel in advanced squamous-cell non-small-cell lung cancer. *N Engl J Med* 2015;373:123–135.
6. Herbst RS, Baas P, Kim DW, Felip E, Perez-Gracia JL, Han JY, Molina J, Kim JH, Arvis CD, Ahn MJ, Majem M, Fidler MJ, de Castro G, Jr., Garrido M, Lubiniecki GM, Shentu Y, Im E, Dolled-Filhart M, and Garon EB: Pembrolizumab versus docetaxel for previously treated, PD-L1-positive, advanced non-small-cell lung cancer (KEYNOTE-010): A randomised controlled trial. *Lancet* 2016;387:1540–1550.
7. Reck M, Rodríguez-Abreu D, Robinson AG, Hui R, Csoszi T, Fulop A, Gottfried M, Peled N, Tafreshi A, Cuffe S, O'Brien M, Rao S, Hotta K, Leiby MA, Lubiniecki GM, Shentu Y, Rangwala R, Brahmer JR, and Investigators K: Pembrolizumab versus chemotherapy for PD-L1-Positive Non-Small-Cell Lung Cancer. *N Engl J Med* 2016;375:1823–1833.
8. Fehrenbacher L, Spira A, Ballinger M, Kowanz M, Vansteenkiste J, Mazieres J, Park K, Smith D, Ardal-Cortes A, Lewanski C, Braith F, Waterkamp D, He P, Zou W, Chen DS, Yi J, Sandler A, Rittmeyer A, and Group PS: Atezolizumab versus docetaxel for patients with previously treated non-small-cell lung cancer (POPLAR): A multicentre, open-label, phase 2 randomised controlled trial. *Lancet* 2016;387:1837–1846.
9. McNagny KM, Pettersson I, Rossi F, Flamme I, Shevchenko A, Mann M, and Graf T: Thrombomucin, a novel cell surface protein that defines thrombocytes and multipotent hematopoietic progenitors. *J Cell Biol* 1997;138:1395–1407.
10. Schopperle WM, and DeWolf WC: The TRA-1-60 and TRA-1-81 human pluripotent stem cell markers are expressed on podocalyxin in embryonal carcinoma. *Stem Cells* 2007;25:723–730.
11. Schopperle WM, Kershaw DB, and DeWolf WC: Human embryonal carcinoma tumor antigen, Gp200/GCTM-2, is podocalyxin. *Biochem Biophys Res Commun* 2003;300:285–290.
12. Hayatsu N, Kaneko MK, Mishima K, Nishikawa R, Matsutani M, Price JE, and Kato Y: Podocalyxin expression in malignant astrocytic tumors. *Biochem Biophys Res Commun* 2008;374:394–398.
13. Doyonnas R, Kershaw DB, Duhme C, Merckens H, Chelliah S, Graf T, and McNagny KM: Anuria, omphalocele, and perinatal lethality in mice lacking the CD34-related protein podocalyxin. *J Exp Med* 2001;194:13–27.
14. Hsu YH, Lin WL, Hou YT, Pu YS, Shun CT, Chen CL, Wu YY, Chen JY, Chen TH, and Jou TS: Podocalyxin EBP50 ezrin molecular complex enhances the metastatic potential of renal cell carcinoma through recruiting Rac1 guanine nucleotide exchange factor ARHGEF7. *Am J Pathol* 2010;176:3050–3061.
15. Snyder KA, Hughes MR, Hedberg B, Brandon J, Hernaez DC, Bergqvist P, Cruz F, Po K, Graves ML, Turvey ME, Nielsen JS, Wilkins JA, McColl SR, Babcock JS, Roskelley CD, and McNagny KM: Podocalyxin enhances breast tumor growth and metastasis and is a target for monoclonal antibody therapy. *Breast Cancer Res* 2015;17:46.
16. Lin CW, Sun MS, and Wu HC: Podocalyxin-like 1 is associated with tumor aggressiveness and metastatic gene expression in human oral squamous cell carcinoma. *Int J Oncol* 2014;45:710–718.
17. Koch LK, Zhou H, Ellinger J, Biermann K, Holler T, von Rucker A, Buttner R, and Gutgemann I: Stem cell marker expression in small cell lung carcinoma and developing lung tissue. *Hum Pathol* 2008;39:1597–1605.
18. Tschernig T, Pabst R, Kasper M, El-Hadi M, and Singh B: Expression of caveolin-1 and podocalyxin in rat lungs challenged with 2-kDa macrophage-activating lipopeptide and Flt3L. *Cell Tissue Res* 2014;356:207–216.
19. Flores-Tellez TN, Lopez TV, Vasquez Garzon VR, and Villatrevino S: Co-Expression of Ezrin-CLIC5-Podocalyxin Is Associated with Migration and Invasiveness in Hepatocellular Carcinoma. *PLoS One* 2015;10:e0131605.
20. Kusumoto H, Shintani Y, Kanzaki R, Kawamura T, Funaki S, Minami M, Nagatomo I, Morii E, and Okumura M: Podocalyxin influences malignant potential by controlling epithelial-mesenchymal transition in lung adenocarcinoma. *Cancer Sci* 2017;108:528–535.
21. Ogasawara S, Kaneko MK, Yamada S, Honma R, Nakamura T, Saidoh N, Yanaka M, Yoshida K, Fujii Y, and Kato Y: PcMab-47: Novel antihuman podocalyxin monoclonal antibody for immunohistochemistry. *Monoclon Antib Immunodiagn Immunother* 2017;36:50–56.

Address correspondence to:

Yukinari Kato
 Department of Antibody Drug Development
 Tohoku University Graduate School of Medicine
 New Industry Creation Hatchery Center
 Tohoku University
 2-1 Seiryomachi, Aoba-ku
 Sendai 980-8575
 Japan

E-mail: yukinari-k@bea.hi-ho.ne.jp

Received: January 11, 2018

Accepted: February 11, 2018